

Case Report

A case of successful yoga prana vidya energy healing treatment of contact dermatitis caused by *Holigarna ferruginea* Marchand

Leelavathi Nayak, Venkata Satyanarayana Nanduri*

Yoga Prana Vidya Ashram, Thally, Tamil Nadu, India

Received: 30 November 2022

Revised: 07 January 2023

Accepted: 10 January 2023

***Correspondence:**

Dr. Venkata Satyanarayana Nanduri,
E-mail: vsnanduri@yahoo.com

Copyright: © the author(s), publisher and licensee Medip Academy. This is an open-access article distributed under the terms of the Creative Commons Attribution Non-Commercial License, which permits unrestricted non-commercial use, distribution, and reproduction in any medium, provided the original work is properly cited.

ABSTRACT

Contact dermatitis is a rash or a condition that makes skin red or inflamed with rashes and pain after direct contact with an allergen or an irritant such as soap, cosmetics, fragrances, jewellery and plants. This paper presents a case of *Holigarna ferruginea* Marchand induced allergic contact dermatitis successfully healed using yoga prana vidya (YPV) healing protocols. This paper uses a case study method collecting patient data before and after healing, and details of YPV intervention applied by trained certified healers for treating this patient. After one day healing, the patient's body temperature became normal. After 2 days of healing, rashes and itching reduced. After further 5 days of healing, the blister on the patient's right hand also completely healed. As an integrated holistic system, the YPV system of healing has been found to be a less expensive modality without the use of any medications and without touching the patient. The successful treatment of contact dermatitis using YPV techniques opens potential avenues for applying these techniques for numerous other skin ailments. Further research is recommended.

Keywords: Yoga prana vidya system®, Contact dermatitis, *Holigarna ferruginea* Marchand

INTRODUCTION

Holigarna ferruginea Marchand

Holigarna is a genus of trees in the family Anacardiaceae of the cashew, mango or sumac family. They grow naturally in India (Kerala, Karnataka and Western Ghats), and are known as Chere in Kannada.¹ This is a poisonous tree; if contacted unknowingly without protection, it would irritate skin chemically and could result in irreversible skin damage. Smoke from burning this wood is dangerously disabling.² Yet, it has several uses such as timber for construction and agricultural implements, and its acrid juice from the stem and fruit-rind is used as a black varnish by the painters. Flowering and fruiting occur seasonally from February to July.³ A study by Srinivas et al found that contact dermatitis due to *Holigarna ferruginea* of the

family Anacardiaceae, was seen in 4 patients. In three cases, the diagnosis was confirmed by patch tests. The presence of pyrocatechol in the acrid juice was detected by simple laboratory procedures.³



Figure 1: *Holigarna ferruginea* Marchand.

Source: www.pilikula.com

A study by Nayak et al reported the histological features of both the bark and leaf of the poisonous plant *Holigarna ferruginea* Marchand responsible for contact dermatitis.⁴

This paper presented a case report of contact dermatitis induced by *Holigarna ferruginea* Marchand successfully treated by Yoga Prana Vidya (YPV) healing protocols.

Yoga prana vidya system®

Yoga prana vidya system® of healing has been successfully applied to a wide range of illness conditions as complementary and as also as an alternative medicine, as is evident from over 60 published research papers.⁵

YPV is an integrated and holistic system, which consists of physical and breathing exercises, meditation techniques, and bioplasmic (Pranic) energy healing techniques. Literature shows published successful case reports on applications of YPV include, treatment of difficult medical cases, diabetes management and control, removing arterial block in heart without surgery, vision improvements for participants of an eye camp, improvements in holistic wellbeing and immunity of participants in a one-month YPV intensive programme,

Role of YPV in first aid and emergency, speedy recovery of COVID patients, treatment of hypothyroidism, lowering academic anxiety and enhancing academic performance of high school children, saving life of a snake-bitten human female, managing the pain and side effects of a Hodgkin lymphoma patient undergoing chemotherapy, healing treatment of a female patient suffering from kneecap dislocation, treatment and cure of PCOS condition, a case of breast cancer successfully treated, de-addiction cases, etc.⁶⁻²⁰ A review of published literature shows some experimental studies also conducted with successful outcomes such as improvements in the wellbeing of prisoners, significant reduction in anxiety and depression in corporate employees, and improvements in the cognitive abilities and social behaviour of mentally challenged children.²¹⁻²³

CASE REPORT

Patient information

The patient is a 14 years old girl, resident of Karnataka who was visiting her grandparents in their village in Udupi district of Karnataka when this incident occurred.

Before YPV healing

There is a tree in that village called Chere tree in Kannada, (botanical name *Holigarna ferruginea* Marchand), and the villagers do not allow children to go near that tree as it causes allergic dermatitis with symptoms such as rashes, swelling, blisters and fever.

On 4th May 2022, this girl went near that tree and played with the branch of the tree as she did not know that it causes dermatitis. She experienced some itching in her hand and body and she neglected it. Gradually she found some rashes but did not inform parents. Next day rashes increased all over her body with swelling and also got a fever.

As she got a blister in her right hand and swelling with rashes on face (Figure 2) her mother observed it, and suspected possible contact with that tree which was confirmed by the girl. Her mother consulted a doctor over the phone who prescribed an antihistamine tablet to relieve the symptoms of allergy. She took one tablet and the same day she consulted a YPV healer and requested for healing.

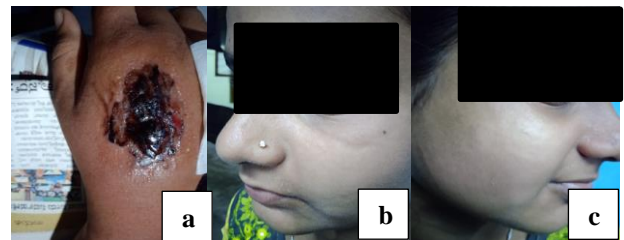


Figure 2: (a) Blister in right hand; (b) swelling on face; and (c) rashes on face.

YPV healing intervention

Healing started on 6th May 2022 for 20 minutes a day, with the following protocols: (a) rhythmic yogic breathing exercises every 2 hours for about 5 minutes using guided track in YPV Sadhana app; (b) follow the light diet with vegetables and fruits; (c) HDP L1 protocol for healing the affected part; (d) standard YPV psychotherapy to reduce the stress; (e) blood cleansing technique used for lungs; (f) organs like liver, kidney and spleen are cleansed; (g) affected parts like right hand, face, neck and entire body are cleansed; (h) basic chakra and all other chakras are cleansed and balanced; and (i) minor chakras of arms and legs are cleansed and energised.

Patient progress due to YPV healing

Next day after the healing started, her body temperature came to normal and swelling in face reduced. Gradually after 2 days rashes in the face and body reduced and black skin of blister in right hand disappeared (Figure 3).

Healing continued further. The affected part and body skin got completely healed and became normal within 7 days of healing (Figure 3) and healing was discontinued from 13th May 2022.

As the patient felt relieved of all symptoms, she felt happy and showed interest to continue YPV practices using YPV sadhana app and to learn YPV healing to become a healer.

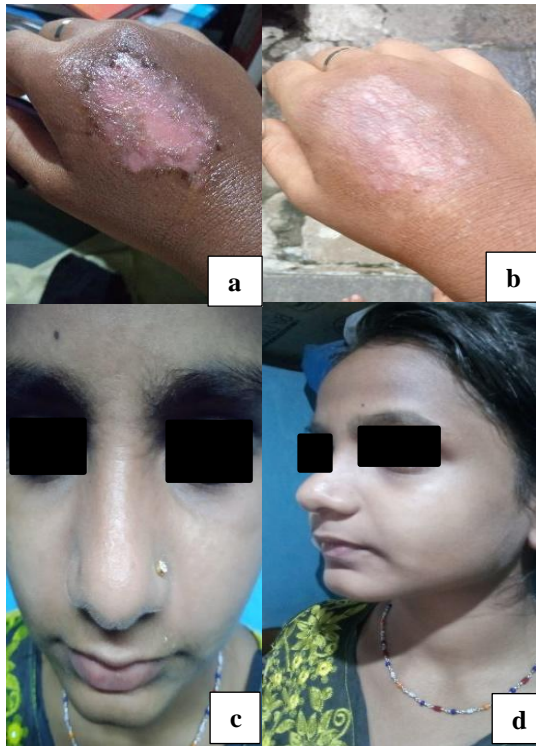


Figure 3: (a) Blister healing progress; (b) blister fully healed; (c) face rash cured; and (d) face rash and swelling cured fully.

DISCUSSION

Contact dermatitis is an allergic or irritant skin reaction caused by an external agent. It is observed that there is scanty literature on use of bio-plasmic energy healing techniques such as YPV to treat this condition. However, there are several home remedies such as applying an anti-itch cream or ointment, anti-itch drug, or applying cool, wet compresses etc.

According to a study by Lakshmi et al, herbal and ayurvedic medications, believed to be ‘mild’ and ‘natural’ are usually sought as the first line of treatment for allergic dermatitis before resorting to ‘stronger’ allopathic medication. There are very few reports of adverse reactions to either topical and/or systemic ayurvedic medications. Massage aromatherapy with ayurvedic oils plays an important role in alleviation of pain.²⁴

CONCLUSION

YPV protocols have been established as Complementary and alternative medicine (CAM) to treat various types of physical and psychological diseases and ill-health conditions. Further research is recommended. YPV system protocols are integrated and holistic, and a working knowledge of the application of YPV techniques for frontline medical workers such as doctors and nurses is recommended to holistically treat and heal patients effectively.

ACKNOWLEDGEMENTS

We would like to thank to Sri Ramana Trust for permission given to use their copyright terms Yoga Prana Vidya System® and YPV®, and also to the patient and her family for sharing the case details in confidence without disclosing patient identity.

Funding: No funding sources

Conflict of interest: None declared

Ethical approval: Not required

REFERENCES

1. Rao SK, Swamy RK, Kumar D, Singh RA, Bhat KG. Flora of Peninsular India, 2022. Available at: <http://florapeninsulaindica.ces.iisc.ac.in/herbsheet.php?id=610&cat>. Accessed on 13 November 2022.
2. Srinivas CR, Krupashanker DS, Naik RP, Lyengar MA. Holigarna Ferruginea Induced Allergic Contact Dermatitis. Indian J Dermatol Venereol Leprol. 1986;52(4):218-9.
3. Pilikula Development Authority. Holigarna ferruginea Marchand, 2022. Available at: https://www.pilikula.com/botanical_list/botanical_name_h/holigarna_ferruginea.html. Accessed on 13 November 2022.
4. Nayak SG, Kulkarni SB, Iyengar MA. Histology of the bark and leaf of a toxic plant holigarna ferruginea march. Anc Sci Life. 1993;12(3-4):327-34.
5. Saluja SK, Nanduri VS. A case of esophageal cancer Stage 2 successfully healed using Yoga Prana Vidya protocols as complementary medicine. Innovative J Med Health Sci. 2022;12(10):2009-13.
6. Neravetla, J, Nanduri, VS. A study into the successful treatment of some difficult medical cases using Yoga Prana Vidya (YPV) Healing System as alternative medicine. Int J Sci Eng Res. 2019;10(7):882-7.
7. Rajagopal AH, Ramya A, Nanduri, VS. Diabetes Management and Control Using Yoga Prana Vidya (YPV) Healing System. J Biol Life Sci. 2019;10(2).
8. Ramya A, Nanduri VS. Cardiac Case Study: Successful Healing Treatment of a 48-Year-Old Male with Block in Heart, Using Yoga Prana Vidya (YPV) Healing System. Saudi J Nurs Health Care. 2019;2(11):353-6.
9. Nanduri VS, Chaitra N. How the participants of a Yoga Prana Vidya (YPV) Eye Camp experienced vision improvements: A Case study. J Comm Health Manag. 2019;6(4):139-46.
10. Neravetla J, Nanduri VS. A study of the effects of Yoga Prana Vidya one-month intensive residential programme for participants on their physical health, psychological well-being and improved immunity. Int J Res Anal Rev. 2020;7(2):18-27.
11. Neravetla J, Nanduri VS. Role of Yoga Prana Vidya (YPV) Healing Techniques in Emergency and First Aid: A Summary of Case Reports. Int J Med Sci Health Res. 2020;4(3):133-46.

12. Nanduri VS, Karnani V. Successful and speedy recovery of COVID patients using Yoga Prana Vidya (YPV) Healing. Covid-19. 2020;1(4):78-82.
13. Revathi R, Janani N, Nanduri VS. Successful healing treatment of Hypothyroidism using Integrated Yoga Prana Vidya (YPV) healing approach as complementary medicine: Case reports. J Prev Med Holistic Health. 2020;6(1):1-7.
14. Ramya A, Kraleti P, Gopal KVT, Nanduri VS. Efficacy of Planetary Peace Meditation (PPM) of Yoga Prana Vidya (YPV) System in Enhancing Academic Performance of High School Children: A Case study. Indian J Psychol Edu. 2020;10(2):59-64.
15. Ramya A, Ashwin V, Divya D, Nanduri VS. Serious snake bite case: successful treatment using yoga prana vidya (YPV) healing system. 2021;5(01):101-10.
16. Jain V, Bindal S, Bhatia PK, Nanduri VS. Managing pain and side effects of a Hodgkin lymphoma female patient undergoing Chemotherapy using Yoga Prana Vidya System as complementary medicine: A case report. Int J Med Sci Academic Res. 2021;05.
17. Dholakia M, Tandon I, Dholakia D, Nanduri, VS. Successful Healing Treatment of Kneecap (Patellar) Dislocation of a Teen Female Patient Using Yoga Prana Vidya System Protocols without Surgery: A Case Report". Acta Scientif Women's Health. 2021;3(11):15-20.
18. Gupta Y, Nanduri VS. A case of PCOS (Polycystic Ovarian Syndrome) treated successfully by the application of Yoga Prana Vidya System through sustained selfpractice, self-healing and self-belief. Int J Med Sci Health Res. 2022;6(02):34-42.
19. Madhavi S, Nanduri VS. A case of Metastatic Breast Cancer treated successfully by using Yoga Prana Vidya (YPV) Healing Methods persistently as complementary medicine and patient self-belief. Int J Med Sci Dent Res. 2022;05(04):37-44.
20. Dube N, Ramya A, Nanduri VS. Successful application of Yoga Prana Vidya therapy and energy healing techniques in de-addiction: An analysis of case series. Int J Intg Med Sci. 2022;9(2):1016-22.
21. Nanduri VS, Revathi R. Effects of Yoga Prana Vidya intervention on psychological wellbeing and criminal attitude of under-trial prisoners. Ind J Psychiatric Social Work. 2020;11(2):1-9.
22. Nanduri VS. A Study on the Effects of Yoga Prana Vidya System (YPV) Intervention at workplace for Corporate Employees and Executives to alleviate Anxiety, Depression and Burnout; and participants' perceptions and experiences of the YPV Intervention. Int J Indian Psychol. 2020;8(3):374-90.
23. Rajkumari K, Bembalkar S, Nanduri VS. A Pilot Study of the Effects of Yoga Prana Vidya (YPV) protocols on social behaviour, cognitive abilities and IQ of mentally challenged children, Paediatric Review. Int J Paed Res. 2021;8(1):7-15.
24. Lakshmi C. Allergic Contact Dermatitis (Type IV Hypersensitivity) and Type I Hypersensitivity Following Aromatherapy with Ayurvedic Oils (Dhanwantharam Thailam, Eladi Coconut Oil) Presenting as Generalized Erythema and Pruritus with Flexural Eczema. Indian J Dermatol. 2014;59(3):283-6.

Cite this article as: Nayak L, Nanduri VS. A case of successful yoga prana vidya energy healing treatment of contact dermatitis caused by *Holigarna ferruginea* Marchand. Int J Res Dermatol 2023;9:81-4.